

Combined Modality of Focused Ultrasound and Radio-Frequency for Non-Invasive Fat Disruption and Body Contouring – Results of a Single Treatment Session

a report by

Dr. Hector Leal

UltraLaser, Monterrey, Mexico

Background: Combining treatment modalities for fat disruption and body shaping has been frequently performed to achieve a synergistic effect. These modalities are usually used with time intervals between treatments due to safety concerns. Focused Ultrasound (FUS) is a well known method to disrupt fat tissue. This technology has a high safety profile when using cavitation effect as opposed to a thermal effect. Our objective was to prove that treating with FUS technology and RF in one session is safe and can achieve meaningful results.

Material and Methods: 24 subjects were treated in the abdomen during a single session which included RF treatment (Reaction™, VIORA) immediately before and after a treatment with non-thermal focused ultrasound (Contour I, UltraShape®). Two ultrasound treatment protocols were used, each in 12 subjects. Subjects were evaluated at day 7, 14 and 28 after the day of treatment. Safety variables included adverse event collection for the whole study population and laboratory evaluation in 12 subjects. Primary efficacy variables included circumference measurements.

Results: At 28 days, combined ultrasound-RF treatment resulted in mean circumference reductions of 3.0cm - 3.4cm depending on the ultrasound protocol used. 93% of subjects experienced a circumference reduction greater than 1.5cm. Only one mild adverse event was reported and was attributed to operator misuse of the RF device. Lab tests were normal throughout the study.

Discussion and Conclusion: Using FUS combined with RF, in one treatment session to disrupt fat tissue for the purpose of body contouring, is safe, effective and well tolerated.

INTRODUCTION

Current invasive technologies for local fat disruption for the purpose of body contouring include liposuction, ultrasound-assisted liposuction and laser-assisted liposuction. There is an increasing demand for non-invasive body contouring treatments that effectively and safely reduces unsightly local fat deposits in men and women.

Focused ultrasound (FUS) applied by Contour I, UltraShape®, targets and selectively destroys local subcutaneous adipose tissue⁽¹⁾. This focused ultrasound technology does not damage neighboring structures such as blood vessels, nerves, connective tissue, or muscles.

Radiofrequency (RF) technologies, which use electrical current, have been introduced as a new approach for the purpose of body contouring although not for local fat disruption.

Combined treatment modalities for fat disruption for the purpose of body contouring are frequently used in order to achieve a synergistic effect. These modalities are usually used with time intervals due to safety concerns.

This study rationale was to test the hypothesis that in subjects treated for local fat deposits for the purpose of body contouring, application of RF modality immediately prior and immediately after Ultrashape® FUS treatment is safe, and may induce a significant body contouring effect after only one single treatment session.

MATERIAL AND METHODS

Patients and Treatment Procedures

Twenty four healthy female subjects were enrolled in this prospective, open label study, conducted in a single center, in Monterrey, Mexico. All subjects were treated in the abdomen during a single session which included combined treatment by Radio-Frequency (Reaction™, VIORA) with non-thermal focused ultrasound (Contour I, UltraShape®). Group A comprised of twelve subjects who were assigned to a combined treatment by RF immediately prior to and immediately after a single pass procedure of high power focused ultrasound. Group B comprised of twelve subjects who were assigned to an intensified combined treatment by RF prior to and immediately after a double pass procedure of high power focused ultrasound. Main inclusion criteria were a body mass index (BMI) of <30 and an abdominal fat thickness of at least 2.5 cm prior to treatment as measured by commercial pinch caliper.

The focused ultrasound treatment was applied according to the manufacturer's instructions using a hand piece whose positioning was monitored and guided by the Contour I real-time video tracking and guidance system. The RF treatment was applied for 15 minutes immediately prior to and an additional 10 minutes immediately after the focused ultrasound treatment in all subjects. The RF frequency mode used was 0.8 MHz which is suitable for deep layer (15-18mm) treatments.

Efficacy and Safety Parameters

Subjects were followed at 14 and 28 days after the treatment session. Primary efficacy variable consisted of circumference reduction at 28 days. Circumference measurements were assessed at three heights in each visit. Efficacy was evaluated by analyzing the greatest reduction achieved out of the three measurements.

Other efficacy variables included photographic assessment for body contouring changes at the treatment area, and subject satisfaction assessed by a questionnaire.

Weight change was monitored to distinguish weight loss-induced body contouring changes (defined as weight reduction/increase greater than 2%) from the combined treatment procedure-induced body contouring changes.

Safety variables included adverse events collection and laboratory assessment for subjects in group B. Blood tests included complete blood count and basic chemistry, liver markers and fasting serum lipids and were collected at 1, 14 and 28 days after treatment.

RESULTS

Efficacy

All subjects completed the combined treatment according the protocol. Twenty eight days after treatment, combined ultrasound-RF treatment resulted in mean circumference reductions of 3.0 cm, 3.4 cm and 3.2 cm, in group A, in group B and in the combined 2 groups, respectively. Fourteen days after treatment, combined ultrasound-RF treatment resulted in mean circumference reductions of 2.8 cm, 3.5 cm and 3.1 cm in group A, in group B and in the combined 2 groups, respectively (Table 1).

TABLE 1: Circumference reduction in all treated subjects

	Combined group A+B	Group A	Group B
Day 14	-3.1	-2.8	-3.5
Day 28	-3.2	-3.0	-3.4

Mean weight change was -0.8 % (0.5kg). At 28 days, three out of 24 subjects had a weight change greater than 2 percent compared to baseline. When excluding these subjects from the analysis, combined ultrasound-RF treatment resulted in mean circumference reductions of 3.1 cm and 3.6 cm in group A and in group B, respectively (Table 2).

TABLE 2: Circumference reduction in treated subjects with less than 2 percent weight change

	Group A	Group B
Day 28	-3.1	-3.6

In the combined group A and B, ninety three percent of subjects experienced a circumference reduction greater than 1.5cm, almost 60 percent experienced a circumference reduction greater than 2.5cm, and 33 percent experienced a circumference reduction greater than 4.0 cm (Figure 1). Photographic assessment revealed a significant body contouring improvement in the treatment area at day 28 (Figure 2 & Figure 3).

Subject Percentage for Different Circumference Reduction Categories

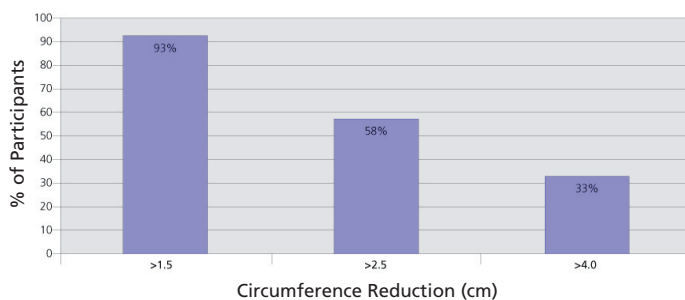


Fig. 1: Subject percentage in different circumference reduction categories after only one single treatment session (Combined group A+B)

Subject satisfaction

100 percent of subjects indicated they are satisfied by the treatment results.

Safety

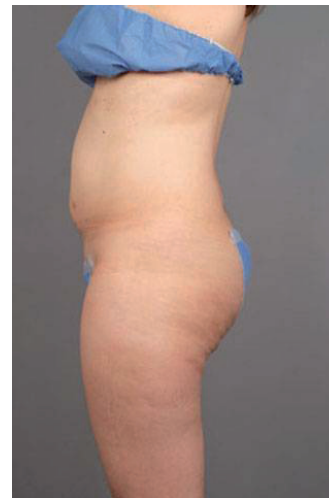No serious adverse events were reported throughout the study. Only one mild adverse event consisting of small blisters was reported and was attributed to faulty operation of the RF device.

The combined treatment was well tolerated in both groups, and no clinically significant treatment-associated changes in laboratory values were observed. Notably, no treatment-induced elevations in serum lipids, lipoprotein levels or liver markers were detected.

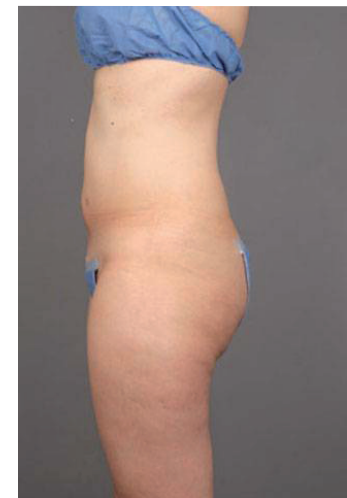DISCUSSION

This study results indicate a significant effect on circumference reduction and body contouring by UltraShape® focused ultrasound when combined with RF & vacuum treatment. These results were achieved by only one single treatment session, and can be noted as early as fourteen or twenty eight days after treatment. This significant circumference reduction effect may indicate a 50% greater mean circumference reduction than was achieved by a single treatment session of focused US alone in the Teitelbaum et al study published in Plastic and Reconstructive Surgery, September 2007 (2,3,4). These results also indicate a trend toward greater

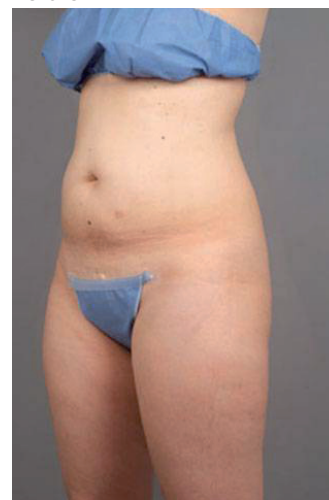Before



After



Before



After

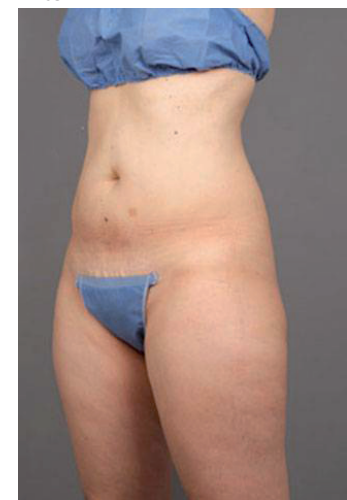


Fig. 2: Before and 28 days after treatment photos of 45 years old female, circumference reduction of 6.8 cm and weight change of 0.2kg.

efficacy of the combined focused ultrasound and RF & vacuum by applying a double pass of focused ultrasound.

The UltraShape® focused ultrasound system induces focused ultrasound wave to disrupt adipocytes by a mechanical effect in order to improve body contouring. This specific effect, termed a cavitation effect, is different from the thermal effect induced by other ultrasound systems intended for body contouring. The cavitation effect induced by UltraShape® system enables selective fat disruption without harming surrounding tissues such as blood vessels and nerves. This selectivity permits treatment sessions with no down time with patients resuming normal activity immediately after treatment.

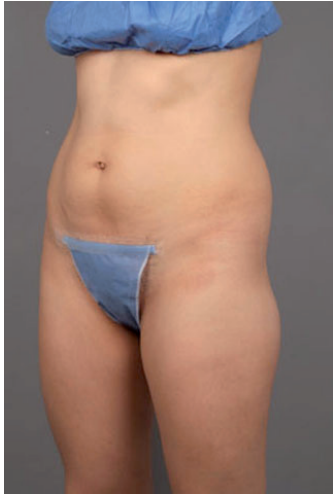RF treatment is indicated for body and faces contouring, temporary reduction in the appearance of cellulite, improvement in local blood circulation, wrinkle reduction and skin tightening. Today, RF treatment is not approved for fat reduction purposes. RF treatment goals are achieved by selection of different operation modes which use different RF frequencies and vacuum level.

Several explanations may exist for the increased efficacy of the combined US and RF modalities found in this study.

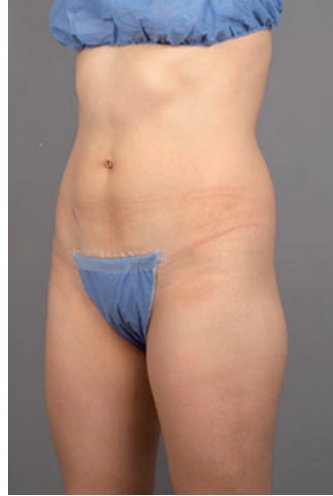While the disruption of adipocytes is achieved only by the focused US, the application of RF treatment may increase its effect and the free fat clearance from the treated area.

The application of RF in its deep layer mode (low frequency) immediately

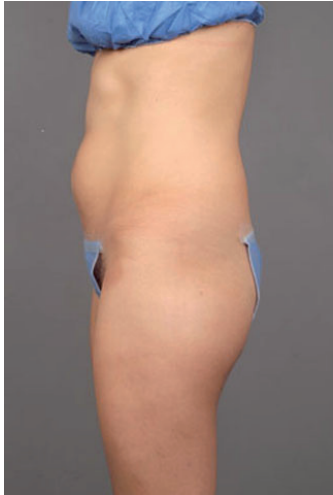Before



After



Before



After

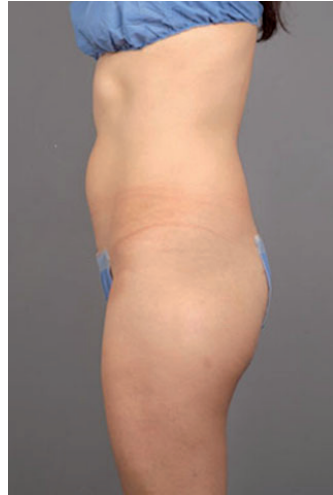

Fig. 3: Before and 28 days after treatment photos of 24 years old female, circumference reduction of 4.9 cm and weight change of 0.5kg

prior to focused US may increase the disruptive effect on adipocytes by increasing the dissolved gasses in the affected area (thus reducing the cavitation threshold for the ultrasonic wave). When used in this deep layer mode, RF application may also accelerate the clearance kinetics of the released triglycerides from the disrupted adipocytes by inducing vasodilatation and increased blood flow. Thus, the natural metabolic pathway in which triglycerides released from adipocytes treated by UltraShape and ultimately travel to the liver⁽⁵⁾ may be accelerated.

Another explanation for the increased effect achieved by the combined treatment is the fact that RF applicator utilizes RF and mechanical vacuum manipulation to maximize the penetration of RF energy into the treatment area.

The vacuum used to induce coupling of the RF applicator to the skin and mechanical massage, may accelerate lymphatic drainage of released triglycerides from the disrupted adipocytes.

The combined single treatment session was well tolerated even when intensified by a second RF session (immediately after the US session) and a double pass US session.

In this study, no serious adverse events were noted and only one local mild adverse event appeared following faulty operation of the RF device. The high safety profile of this combination of body contouring modalities may be explained by the fact that focused ultrasound applied by UltraShape® technology induces a cavitation effect rather than a thermal

effect. Therefore, the combination of therapies does not add up to a thermal injury to adjacent tissues such as blood vessels, nerves or skin.

The study results also indicate a normal lipid profile and liver markers throughout the study for the intensive treatment group. This fact may be explained by redundancy of normal metabolic pathway involved when focused ultrasound is applied by UltraShape® technology.

CONCLUSION

A single treatment session of combined modality of focused ultrasound and radio-frequency for non-invasive fat disruption and body contouring is safe and well tolerated. The single treatment protocol presented here shows significant circumference reduction achieved as soon as 14 days after the treatment, and provides a new opportunity for clinics who want to offer a single session with immediate outcome.

REFERENCES

1. Brown S et al. *Plast. Reconstr. Surg.* 124: 92, 2009
2. Moreno-Moraga J et al. *Lasers Surg. Med.* 39:315–323, 2007
3. Teitelbaum S A et al. *Plast. Reconstr. Surg.* 120: 779, 2007
4. Leal H et al. presented at the American Society for Laser Medicine and Surgery conference 2008
5. Brown S http://www.bodyclinic.ch/img/Fatmetabolism_after_treatment_with_Contour_I_by_Ultrashape.pdf

